

Accession Sticker 1 of 1



158360779

## Belle Collett, Jr. (15975)

Species: Canine  
Breed: Cocker Spaniel, American  
Gender: Female Spayed  
Age: 8 y (04/10/2013)

## KLEINBROOK ANIMAL HOSPITAL (25703)

12202 Bammel North Houston Rd  
Houston, TX 77066

Phone: 281-444-8387  
Veterinarian: Jacquelyn D. Marshall, DVM

## Lab Use Only

## Details

Collection Date: 07/27/2021  
Previous Reference #:   
Order Notes

## Tests

STD BIOPSY W/OUT DESC (2711)  
Specimen in 10% formalin

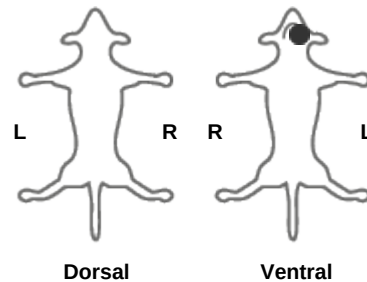
## Sample Source

Mucocutaneous junction - specify in Clinical History

## Sample Type

Excisional

## Sample Location



## Clinical History

Presented last week with left lower lip margin tumor and significantly enlarged left mandibular LN. Thoracic radiographs indicate disseminated metastatic lesions in the lungs. Cytology suggestive of amelanotic melanoma. Mass has been bitten and is infected. Excised mass for paliative purposes.

Contact Us  
**1-888-433-9987**